

## Mutations in the endosomal ESCRTIII-complex subunit CHMP2B in frontotemporal dementia

Gaia Skibinski<sup>1</sup>, Nicholas J Parkinson<sup>1</sup>, Jeremy M Brown<sup>2</sup>, Lisa Chakrabarti<sup>1,12</sup>, Sarah L Lloyd<sup>1</sup>, Holger Hummerich<sup>1</sup>, Jørgen E Nielsen<sup>3,4</sup>, John R Hodges<sup>5</sup>, Maria Grazia Spillantini<sup>6</sup>, Tove Thusgaard<sup>7</sup>, Sebastian Brandner<sup>1,8</sup>, Arne Brun<sup>9</sup>, Martin N Rossor<sup>8</sup>, Anders Gade<sup>4,10</sup>, Peter Johannsen<sup>4</sup>, Sven Asger Sørensen<sup>3</sup>, Susanne Gydesen<sup>11</sup>, Elizabeth MC Fisher<sup>8</sup> & John Collinge<sup>1,8</sup>

**We have previously reported a large Danish pedigree with autosomal dominant frontotemporal dementia (FTD) linked to chromosome 3 (FTD3). Here we identify a mutation in CHMP2B, encoding a component of the endosomal ESCRTIII complex, and show that it results in aberrant mRNA splicing in tissue samples from affected members of this family. We also describe an additional missense mutation in an unrelated individual with FTD. Aberration in the endosomal ESCRTIII complex may result in FTD and neurodegenerative disease.**

FTD is the second most common cause of presenile dementia, accounting for up to 20% of cases<sup>1</sup>. FTD is genetically heterogeneous, with associated loci identified on chromosomes 9 (ref. 2) and 17 (ref. 3). We previously reported linkage of a dominant FTD phenotype segregating within a large Danish family to a pericentromeric region of 12 cM on chromosome 3 (FTD3). The brains of individuals with FTD3 have no distinctive neuropathological features. They show global cortical and central atrophy, but no  $\beta$ -amyloid deposits are found and immunostaining for tau is not suggestive of a tauopathy<sup>4,5</sup>. Onset of dementia is typically in the late 50s and is initially characterized by behavioral and personality changes including apathy, restlessness, disinhibition and hyperorality, progressing to stereotyped behaviors, non-fluent aphasia, mutism and dystonia, with a marked lack of insight. The family spans six generations with over 450 known members (Supplementary Fig. 1 online).

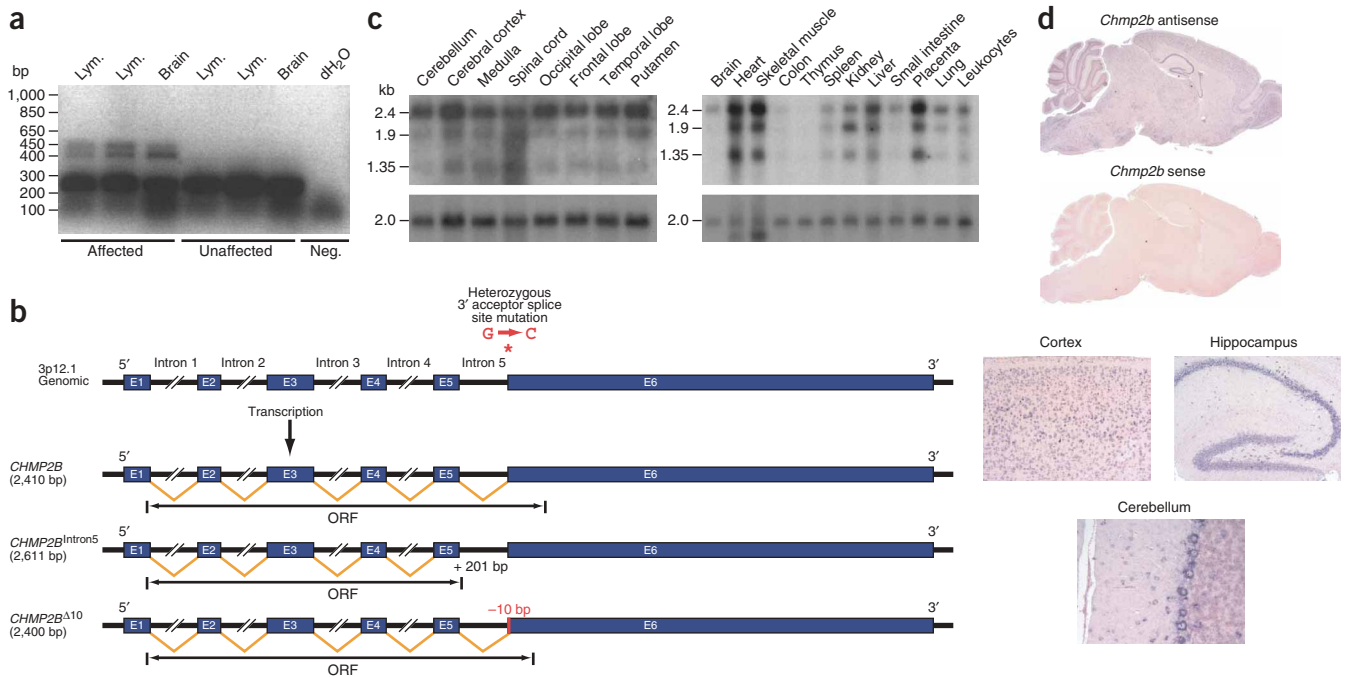
Markers within the non-recombinant region were used to genotype family members, and a common haplotype spanning an estimated

15.5-Mb interval defined by markers *D3S3581* and *D3S3690* was seen in all affected individuals (Supplementary Fig. 2 and Supplementary Methods online). We sequenced several candidate genes from within the critical region, selected on the basis of likely function and pattern of expression, and found only one mutation, a G-to-C transition in the acceptor splice site of exon 6 in *CHMP2B* (charged multivesicular body protein 2B, also known as chromatin-modifying protein 2B) (Supplementary Fig. 3 online), which encodes a component of the ESCRTIII complex<sup>6</sup>. This change segregated in all 11 affected family members screened and was not seen in 14 unaffected family members, 120 Centre d'Étude du Polymorphisme Humain (CEPH) control samples or 100 control DNA samples from unaffected Danes. This mutation alters the highly conserved splice-site consensus sequence and is predicted to disrupt processing of *CHMP2B* mRNA.

We carried out RT-PCR amplification of *CHMP2B* on total RNA extracted from brain samples and lymphoblast cell lines from affected and unaffected family members and unrelated controls. Two abundant transcripts not previously identified were found in samples from affected individuals (Fig. 1a). Subcloning and sequence analysis of these aberrant amplification products showed either inclusion of the 201-bp intronic sequence spanning exons 5 and 6, referred to as *CHMP2B*<sup>Intron5</sup>, or a short deletion resulting from the use of a cryptic splice site mapping 10 bp from the 5' end of exon 6, *CHMP2B* <sup>$\Delta$ 10</sup> (Fig. 1b). We observed an additional aberrant amplification product in samples from affected individuals but were unable to subclone or sequence it. Further analysis suggested that this band was a heteroduplex formed between wild-type and *CHMP2B*<sup>Intron5</sup> amplification products (data not shown).

To investigate whether the *CHMP2B* locus has a broader involvement in FTD, we sequenced all exons and splice sites (see Supplementary Table 1 online) from the genomic DNA of 400 unrelated European individuals with an FTD phenotype, of whom 89 had a family history of the condition. This sequence analysis identified a G442T substitution in exon 5, in one affected individual, that was not detected in 100 normal individuals from the CEPH dataset (Supplementary Fig. 3 online). This individual had dementia (age of onset 69 years) involving progressive naming and comprehension deficits along with mild disinhibition and irritability. Formal neuropsychometry confirmed the classic features of semantic dementia. Magnetic resonance imaging revealed mild bifrontal and marked left temporal lobe atrophy, and single-photon-emission computed tomography (SPECT)

<sup>1</sup>MRC Prion Unit, Institute of Neurology, University College London, London, UK. <sup>2</sup>Department of Neurology, Addenbrooke's Hospital, Cambridge, UK. <sup>3</sup>Department of Medical Biochemistry and Genetics, Section of Neurogenetics, The Panum Institute, University of Copenhagen, Denmark. <sup>4</sup>Memory Disorders Research Unit, The Neuroscience Centre, Copenhagen University Hospital, Rigshospitalet, Copenhagen, Denmark. <sup>5</sup>MRC Cognition and Brain Sciences Unit, Department of Neurology, Addenbrooke's Hospital, Cambridge, UK. <sup>6</sup>Centre for Brain Repair, Department of Clinical Neurosciences, Cambridge University, Cambridge, UK. <sup>7</sup>Parkvaenget Nursing Home, Holstebro, Denmark. <sup>8</sup>Department of Neurodegenerative Disease, Institute of Neurology, University College London, UK. <sup>9</sup>Department of Pathology, University Hospital of Lund, Lund, Sweden. <sup>10</sup>Department of Psychology, University of Copenhagen, Rigshospitalet, Denmark. <sup>11</sup>Department of Psychiatry, Central Hospital, Holbaek, Denmark. <sup>12</sup>Present address: Department of Laboratory Medicine, University of Washington Medical Center, Seattle, Washington, USA. Correspondence should be addressed to E.M.C.F. (e.fisher@prion.ucl.ac.uk).



**Figure 1** Genomic and transcriptional defects of *CHMP2B*. **(a)** RT-PCR across exons 4 and 6 identified two aberrant products in cDNA from lymphoblast cell lines (Lym.) and brain in affected individuals. Neg., negative control. **(b)** *CHMP2B* genomic structure, position of mutation and resulting transcripts. Transcript *CHMP2B*<sup>Intron5</sup> retains intron 5. Transcript *CHMP2B*<sup>Δ10</sup> uses a cryptic splice site within exon 6. cDNA lengths are based on mutant ORF sequences and GenBank sequence BC001553.1. **(c)** Northern blots containing total RNA from human adult brain regions and other tissues were hybridized with a *CHMP2B* cDNA probe (or human β-actin as a control; below). **(d)** *In situ* hybridization of mouse *Chmp2b* sense and antisense riboprobes on sequential sagittal sections of mouse brain. Images below show higher magnification of cortical, hippocampal and cerebellar subregions displaying prominent staining.

showed reduced perfusion with the same distribution. There was no clear family history of neurodegenerative disease.

Human CHMP2B (CHMP2.5, CGI-84) is a protein of 213 amino acids containing predicted coiled-coil, Snf-7 and acidic C-terminal domains. The yeast ortholog, Vps2, was initially identified in a large-scale systematic mutagenesis screen for unusual vacuolar protein sorting (vps) phenotypes in *Saccharomyces cerevisiae*<sup>7</sup>. Disruption of the *VPS2 (DID4)* gene in yeast results in the formation of dysmorphic hybrid vacuole-endosome organelles termed class E structures. Fifteen vps mutants displaying class E structures have been described, the majority of which are components of ESCRT complexes (endosomal secretory complex required for transport) I, II or III<sup>7,8</sup>.

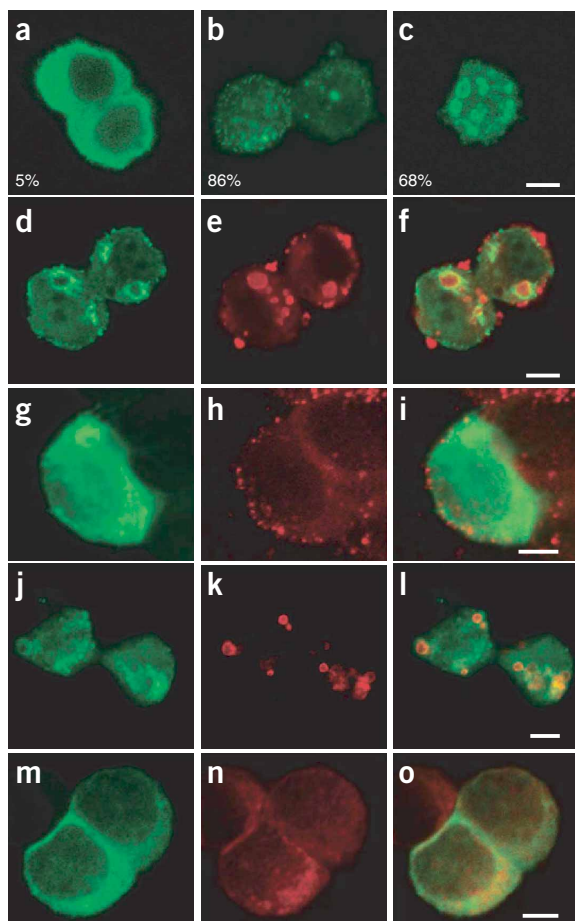
Yeast Vps2 is part of the ESCRTIII complex, which is formed transiently on the limiting membrane of multivesicular bodies (MVBs) after recruitment of component peptides including Vps2, Vps24, Snf7 and Vps20 from the cytosol<sup>7</sup>. Dysfunction of these components or of Vps4, an ATPase required for active dissociation of the ESCRTIII complex, results in an inability of the MVBs to internalize membrane-bound cargo<sup>7,9</sup>.

Northern-blot analysis showed that wild-type *CHMP2B* is expressed in multiple human tissues and in all major regions of the brain, including the frontal and temporal lobes (Fig. 1c). The most abundant transcript is approximately 2.4 kb, supported by a GenBank predicted *CHMP2B* sequence of 2.41 kb. In addition, our northern-blot analysis showed transcripts of approximately 1.9 kb and 1.35 kb suggestive of alternative 5' and 3' untranslated regions (data not shown). *In situ* hybridization of mouse brain revealed widespread expression in all neuronal populations (Fig. 1d). We observed relatively enhanced expression in the hippocampus, frontal

and temporal lobes and in both granule and Purkinje cells of the cerebellum. No astrocytes or oligodendrocytes were labeled. This gene is expressed in numerous tissues that show no known disease phenotype, which mirrors findings in other neurodegenerative disease and suggests that there are other cellular processes underlying the mechanism of neurodegeneration.

Predicted translation of the three mutant transcripts indicates a 36-amino-acid truncation affecting predicted α-helical and Snf-7 domains of the protein's acidic C terminus for *CHMP2B*<sup>Intron5</sup>, a replacement of the same region with an abnormal 29-amino-acid C terminus for *CHMP2B*<sup>Δ10</sup>, and a missense D148Y substitution in the Snf-7 domain for *CHMP2B*<sup>G442T</sup>. The amino acid at this position is highly conserved in *CHMP2B* orthologs (Supplementary Fig. 4).

We sought direct evidence for the pathogenicity of mutant *CHMP2B*<sup>Δ10</sup> or *CHMP2B*<sup>Intron5</sup> by investigating their effects on the late endosome. Specifically, we transfected rat PC12 cells with constructs expressing full-length recombinant CHMP2B isoforms under a constitutive cytomegalovirus promoter. After 48 h, cells transfected with the wild-type CHMP2B construct showed a generalized cytosolic expression pattern for the recombinant protein (Fig. 2a). Cells expressing mutant *CHMP2B*<sup>Δ10</sup> or *CHMP2B*<sup>Intron5</sup> protein had aberrant structures dispersed throughout the cytosol and showed isoform-specific staining patterns. We observed similar results with U2OS cells (data not shown). *CHMP2B*<sup>Δ10</sup>-expressing cells showed widely distributed small punctate bodies, whereas those expressing *CHMP2B*<sup>Intron5</sup> had fewer aberrant bodies of a greater relative size (Fig. 2b,c). Confocal analysis of these structures in cells expressing *CHMP2B*<sup>Intron5</sup> showed that the mutant protein accumulated on the outer membrane of the larger aberrant bodies, with no apparent luminal staining (Fig. 2c,d).



To investigate whether these aberrant bodies represent dysmorphic endosomes, cells expressing CHMP2B isoforms were pulse-chase labeled with fluorescent dextran, an exogenous marker of the endosomal pathway<sup>10</sup>. Dextran accumulated in the lumen of the larger aberrant bodies of cells expressing CHMP2B<sup>Intron5</sup> (Fig. 2d–f), but did not always accumulate in or associate with the smaller punctate bodies found in some cells expressing CHMP2B<sup>Intron5</sup> or CHMP2B<sup>Δ10</sup> (Supplementary Fig. 5). Further analysis using antibodies to CD63, a specific marker of late endosomal and lysosomal organelles<sup>11</sup>, showed colocalization of the mutant protein and CD63 on the periphery of the larger aberrant structures found in cells expressing CHMP2B<sup>Intron5</sup> (Fig. 2j–l). In contrast, smaller aberrant bodies from CHMP2B<sup>Intron5</sup>- and CHMP2B<sup>Δ10</sup>-expressing cells colocalized only partially (Supplementary Fig. 5). Partial colocalization was also seen in CHMP2B<sup>Wild-type</sup>-expressing cells (Fig. 2m–o).

Here we provide evidence that mutation in the *CHMP2B* gene, which may cause a primary defect in the ESCRTIII complex, leads to neurodegenerative disease. We have shown that the mutation found in the large Danish kindred with FTD disrupts CHMP2B localization in cell culture and results in the formation of dysmorphic organelles of the late endosomal pathway. Notably, similar aberrant endosomal structures are seen in conjunction with ectopic overexpression of *ALSIN*, a gene associated with a recessive form of motor neuron disease<sup>12</sup>. In addition, spastin, a protein mutant in hereditary spastic paraplegia, another form of motor neuron disease, interacts directly with the ESCRTIII component CHMP1B<sup>13</sup>. Histopathological abnormalities are also seen in endosomes in preclinical stages of

**Figure 2** Overexpression of mutant CHMP2B isoforms produces an aberrant phenotype. Undifferentiated PC12 cells were transfected with expression constructs encoding recombinant protein c-Myc-CHMP2B, c-Myc-CHMP2B<sup>Δ10</sup> or c-Myc-CHMP2B<sup>Intron5</sup> and stained with FITC-conjugated antibody to c-Myc. (a–c) Confocal analysis showed that wild-type CHMP2B (a) resulted in generalized cytoplasmic expression, whereas the aberrant isoforms CHMP2B<sup>Δ10</sup> (b) and CHMP2B<sup>Intron5</sup> (c) resulted in cytoplasmic punctate bodies of variable size. The percentage of c-Myc-positive cells containing punctate aberrant bodies of variable size is indicated for each CHMP2B isoform. (d–i) The large aberrant bodies of CHMP2B<sup>Intron5</sup> sequestered an endocytic tracer (d–f), in contrast to wild-type CHMP2B (g–i). After transfection, PC12 cells were fixed and stained with antibody to c-Myc to show expression of CHMP2B<sup>Intron5</sup> and wild-type CHMP2B (d,g). Before fixation, cells were incubated in fluorescently labeled dextran (e,h). The images were merged to assess colocalization (f,i). (j–o) The aberrant bodies of CHMP2B<sup>Intron5</sup> were shown to colocalize with CD63 (j–l), in contrast to wild-type CHMP2B (m–o). After transfection, cells were doubly stained with antibodies to c-Myc (j,m) and to CD63 (k,n) and the images merged to assess colocalization (l,o). Bar, 5 μm.

neuropathological disease such as Alzheimer disease, Neimann-Pick type C disease and Down syndrome<sup>14</sup>.

FTD3 is, to date, unique to one Danish kindred and we have not yet seen cosegregation of *CHMP2B* mutations in other FTD kindreds to strengthen the evidence for their causality; it remains possible that an undetected coding or non-coding change elsewhere in the 15.5-Mb disease haplotype region is responsible. However, the two mutations described here lie in extremely highly conserved domains and are predicted to perturb protein function substantially. Furthermore, expression of mutant CHMP2B in cell culture results in a phenotype consistent with the known biology of its yeast homolog Vps2. Attempts to model FTD3 in transgenic mice are underway. There is increasing evidence for disruption of endosomal trafficking in neurodegeneration, and together with the considerable phenotypic overlap that exists between FTD and other neurodegenerative diseases<sup>15</sup>, this study should encourage a search for mutations in genes encoding proteins of the ESCRT I, II and III complexes in other neurological conditions in which a defined genetic cause has not yet been identified.

#### ACKNOWLEDGMENTS

We thank all members of the Danish family for their support of this research; J. Hardy for his early contribution to research on this kindred; G. Schiavo, G. Banting, J. Linehan, C. Powel, P. Jat, A. Clarke and E. Englund for their assistance with these studies; and R. Young for graphics. This work was funded by the UK Medical Research Council.

#### COMPETING INTERESTS STATEMENT

The authors declare that they have no competing financial interests.

Received 22 April; accepted 29 June 2005

Published online at <http://www.nature.com/naturegenetics/>

- Knopman, D.S. *et al. Neurology* **40**, 251–256 (1990).
- Hosler, B.A. *et al. J. Am. Med. Assoc.* **284**, 1664–1669 (2000).
- Wilhelmsen, K.C. *et al. Am. J. Hum. Genet.* **55**, 1159–1165 (1994).
- Gydesen, S. *et al. Neurology* **59**, 1585–1594 (2002).
- Yancopoulos, D. *et al. J. Neuropathol. Exp. Neurol.* **62**, 878–882 (2003).
- Martin-Serrano, J., Yarovoy, A., Perez-Caballero, D. & Bieniasz, P.D. *Proc. Natl. Acad. Sci. USA* **100**, 12414–12419 (2003).
- Babst, M. *et al. Dev. Cell* **3**, 271–282 (2002).
- Katzmann, D.J. *et al. Cell* **106**, 145–155 (2001).
- Babst, M. *et al. EMBO J.* **17**, 2982–2993 (1998).
- Harrison, R.E. *et al. Mol. Cell. Biol.* **23**, 6494–6506 (2003).
- Fukuda, M. *J. Biol. Chem.* **266**, 21327–21330 (1991).
- Kunita, R. *et al. J. Biol. Chem.* **279**, 38626–38635 (2004).
- Reid, E. *et al. Hum. Mol. Genet.* **14**, 19–38 (2005).
- Nixon, R.A. *Neurobiol. Aging* **26**, 373–382 (2005).
- Collinge, J. *et al. J. Neurol. Neurosurg. Psychiatry* **57**, 762–768 (1994).